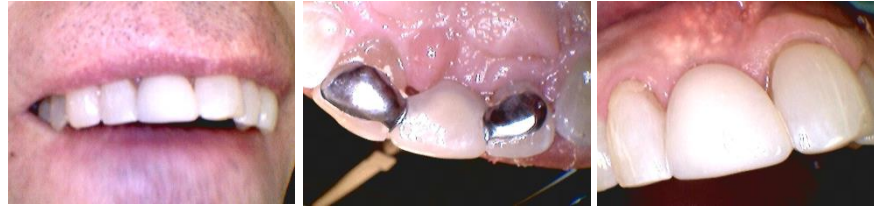

Case Study 4

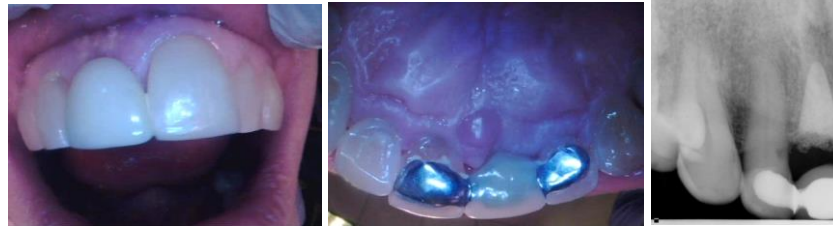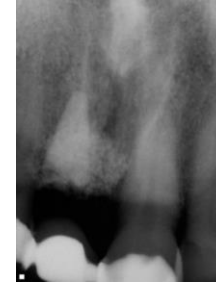
T. Bob Davis, DMD

CASE REPORT – INSTALLMENT #4

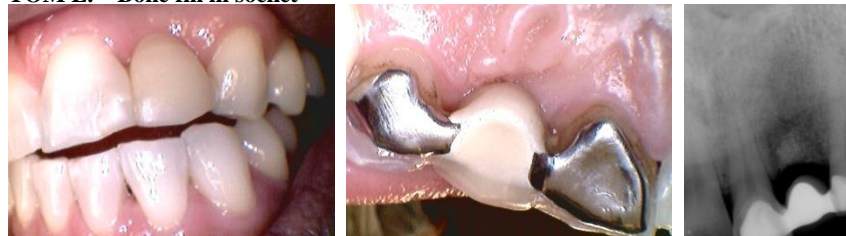STEVE C. → Bone fill in socket



This new patient at age 32 had a badly broken down and severely buccally abscessed tooth #8 when we first saw him, lots of bone loss, from severe external resorption. We chose after weeks /months of consultation with him to place a Rocky Mountain hydroxyapatite root form in the socket with calcitek hydroxyapatite pellets to expand the gum where the buccal plate had been destroyed. The calcitek hydroxyapatite pellets showed through the gum as white speckled particles but the lip doesn't rise that high to show. This was done 9-28-1987, never been loose, never been sore, never caused one bit of problem! As good today as it was over 28 years ago. Comspan bonding used. Note solid bone after over a quarter century! NO reduction in gingiva either! Conservative care equals Quality care!

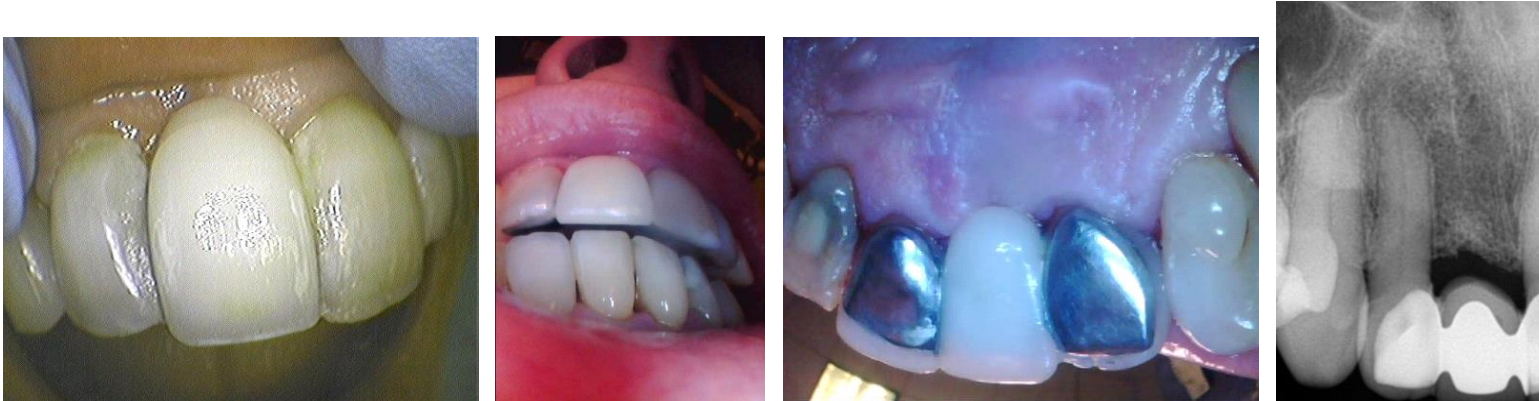
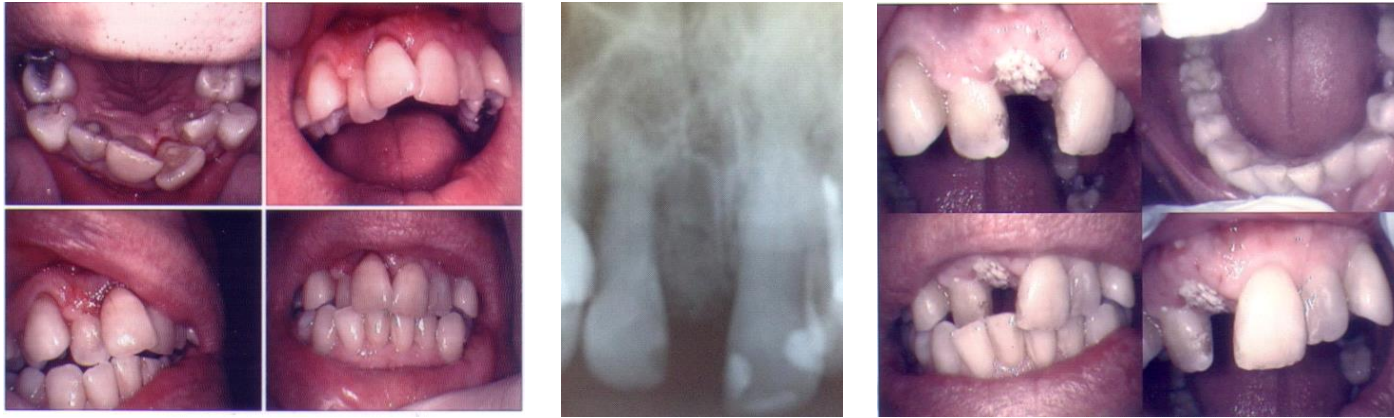
TOM L. – Bone fill in socket



The patient had a traumatic injury that resulted in loss of #10 while in college. We placed Hydroxyapatite in socket after extraction and used a flipper for 8 weeks. The Maryland Bridge was placed 5-31-1989 with Comspan bonding. It has never been altered and is as firm as when seated over 25 years. Note how small the lingual wing on #11 but over 25 years bond success! Superb esthetics for over 25 years! And bone fill normal! Note no gum recession, no bone loss, and minimal color difference after a quarter century!

JOHN F.



This 70 year old patient presented with a fractured and non-restorable #8 as referred by an endodontist. Severe anterior and generalized crowding made an implant not a possibility and dictated alternative. Patient chose removable expansion appliances for six months and clear braces for eight months. The split tooth #8 was removed and bone fill with fabric and Coe-Pak were placed on the first appointment when the expansion began. Exceptional ortho results allowed for placement of the MB two years later. Having experienced great success for over seven years, the patient is extremely pleased over the choices. You are never too old to have great quality dental care!