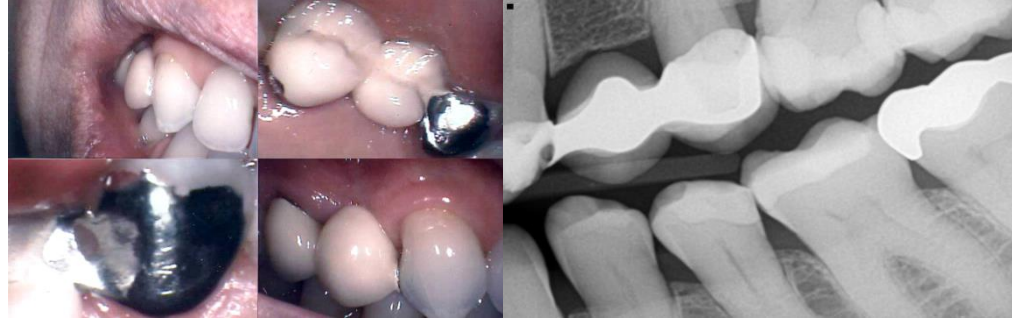


Case Study 10

T. Bob Davis, DMD

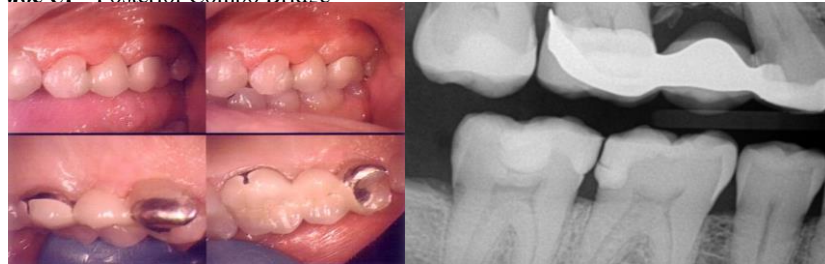
CASE REPORT – INSTALLMENT #10
Combination Bridges

INGE C. - Posterior Combo Bridge



This Combination Bridge was placed on teeth #11 and #13 on December 12, 1994. ZnOPO₄ was used for the metal to porcelain crown and Panavia resin cement on the etched wing. With over 21 years use, no debonding, note the excellent esthetics. Patient states “I never think of the bridge, it is now just part of me!” Note solid cortical plate healed, no gingival retraction, thus excellent esthetics, and easily maintained crown on #13!

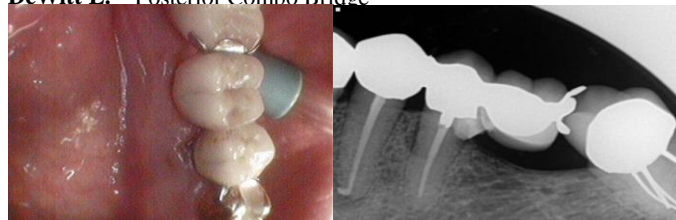
Joe U. – Posterior Combo Bridge



Combo MB #3X5,
pontic #4, seated #3 on
6/30/2005 with RelyX
Luting Cement, #5 with
RelyX ARC. Note
excellent esthetics!
YDL Dallas Lab.

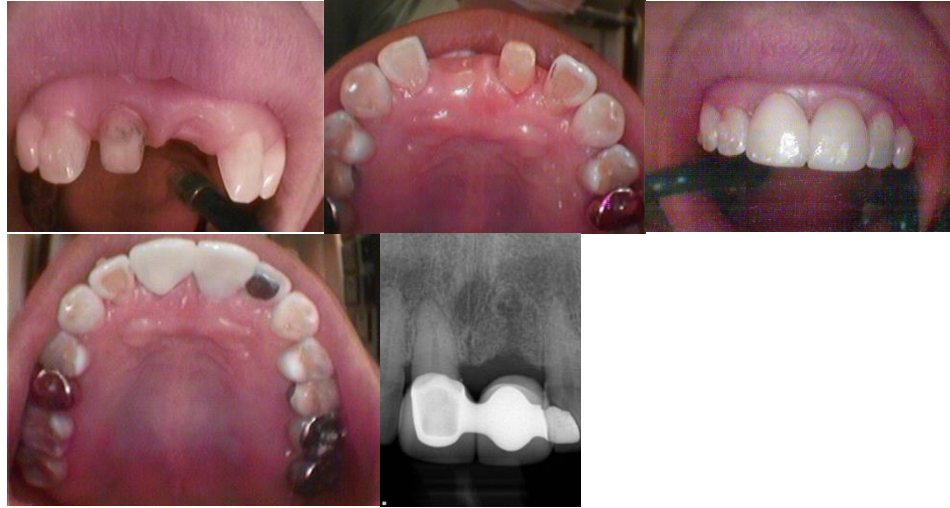Over 10 years of completed
satisfied service!

DeWitt E. – Posterior Combo Bridge



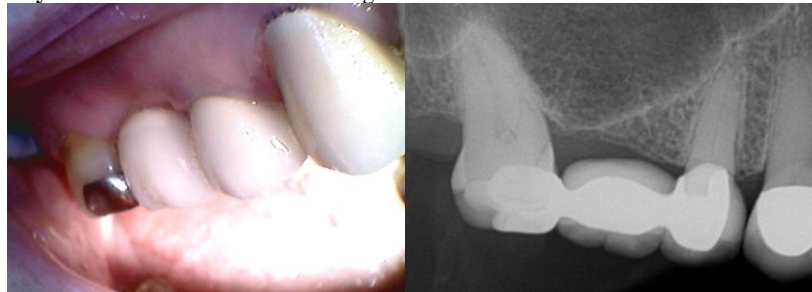Seated on 2/4/1997, #18 with ZnOPO₄ Flecks Cement and #20 with Enforce.
Lab work done by Reed Lab. Note all teeth have root canals plus recent decay repair on distal cervical #20. Age and decreased hygiene can challenge the roots of ANY filling/crown/tooth Still a current regular patient.
Placed crown on #20 2/4/97 with ZnOPO₄ and with enforce wing attachment on #17. The bond has long since gone, but the bridge has been stable for 19years!

Helen K. → Anterior Combo Bridge



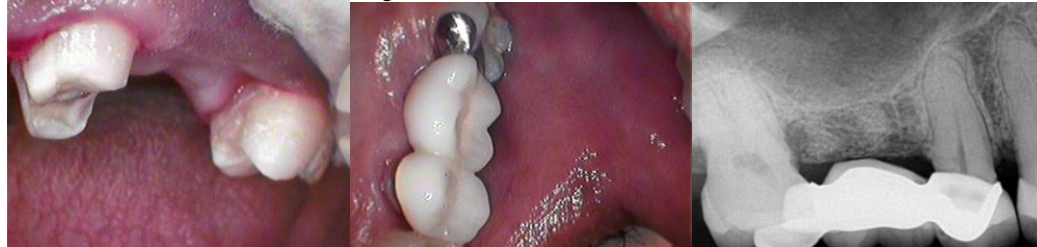Patient had non-restorable #9 and old crown #8. Extracted #9, placed putty bone fill. Did clear braces for six months. Placed Combo Bridge #8 porcelain to metal crown abutment, #9 pontic, #10 MB lingual wing. Continued clear braces for 8 months additional. She has had 4 years longevity so far with great maintenance. Highland Lab.

Coy R. → 4/24/07 Post Combo Bridge



#2 had old MO Amalgam changed to composite. #4 had old crown with recurrent deep decay replaced with porcelain fused to metal and #3 pontic, replacing the missing tooth #3. Nearly 8 years success/ YDL Lab.

Larry B. → 1/19/12 Post Combo Bridge



#3 non-restorable was extracted and placed with bone fill with biomembrane. #2 MB wings and #4 porcelain fused to metal crown seated with #3 pontic. 4 years success thus far. Highland Lab.