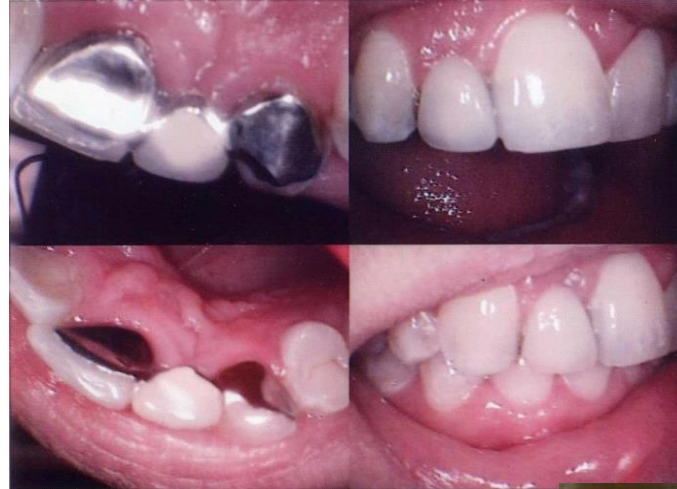

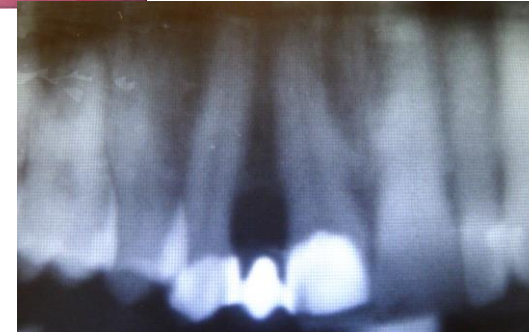Case Report 1

T.Bob Davis, DMD

CASE REPORT – INSTALLMENT #1
LEANNE C. - OLDEST



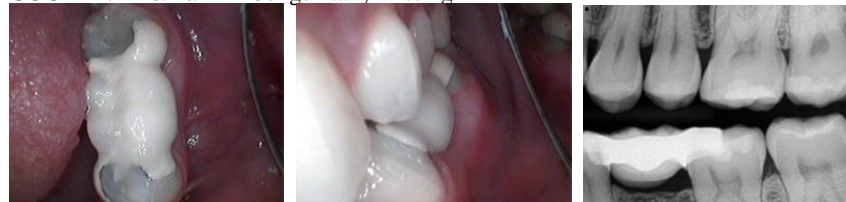Congenitally missing tooth #7 had been temporized with a single tooth flipper for many years. For her graduation from high school at age 18, her parents chose the Maryland Bridge as a gift. Placed on September 13, 1982, with Comspan resin cement after acid bath electroetch, this bridge is still in service after 33 years with no debond. The lab work was done by Keller Lab in Missouri.



Upon inquiring after 28 years if she wanted to replace it due to gum recession on all teeth from age, she responded it was so natural, felt and looked normal to her, and liked as it has been these years! This is proof of the longevity of the technology, of the patient acceptance of conservative restoration, and of the economic value of such a quality restoration!

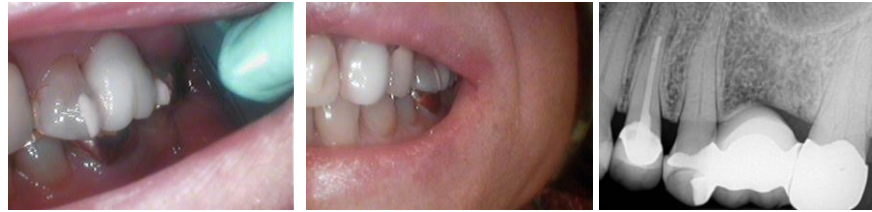Note the x-ray of roots #6 and #8. Clearly to place an implant orthodontics would be necessary! Then months of osseo-integration would have delayed esthetic completion of such a case for upwards of two to three years (ortho & implant). This case was finished in three weeks. Alternately, should better replacements become available; these teeth have such minimal preparation that new technology remains available decades after initial placement. Thus this bridge saves teeth for healthy future choices!

COURTNEY 5/16/12 – Congenitally missing



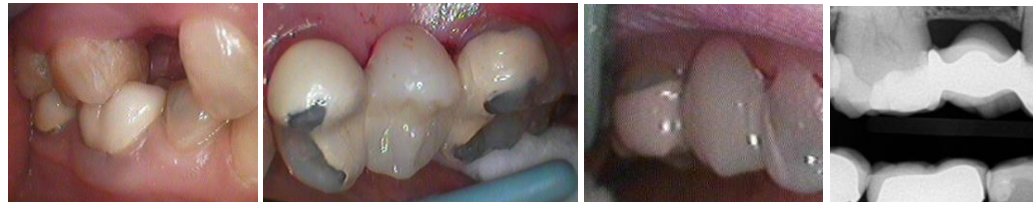Note beautiful esthetics and excellent bone relation! Young mother of two with excellent dental care and minimal repairs. #20 and 29 were congenitally missing.

SHERRY 9/28/12



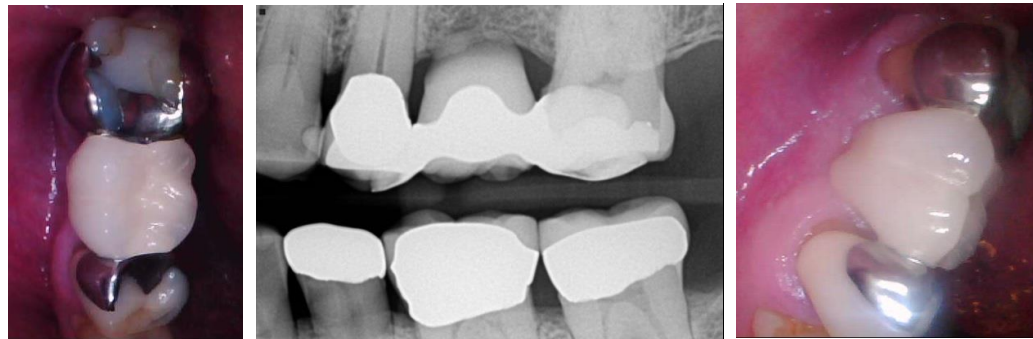
Replacing old failed root canal/split tooth with large hole filled with bone fill. Note excellent fit to gum and bone! Reestablishes normal function with Full Gold Crown on #15.

MARCIA 4/24/12



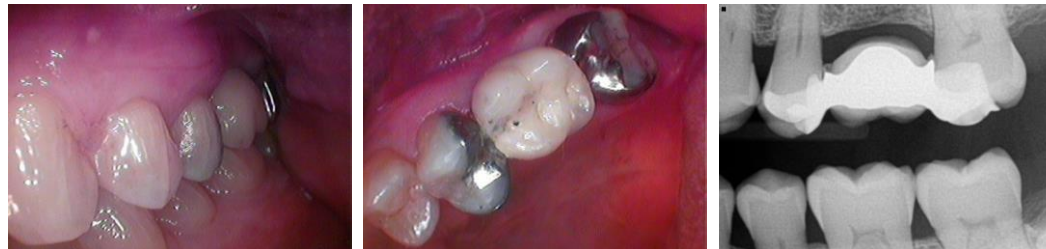Note lingual view, firm grip on bicuspid and molar!

Dr. STEVE 4/15/10



Esthetics not a concern, longevity more valued. Note excellent grips on both abutments.

GREGG 3/17/09



Note front view of buccal of bicuspid does NOT show metal wing! Conservative, esthetic, and excellent gingiva/bone health! Replaces old split molar quickly and conservatively in keeping with other excellent teeth.